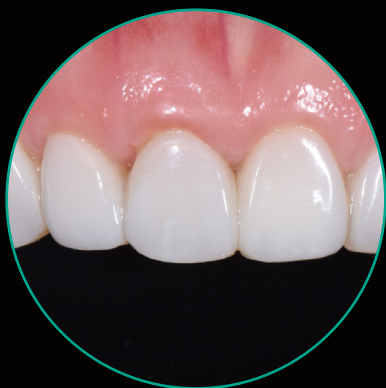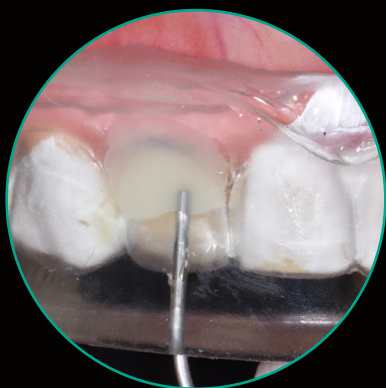

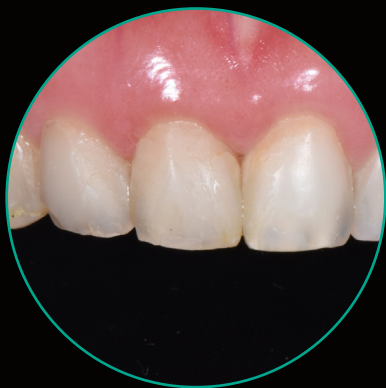
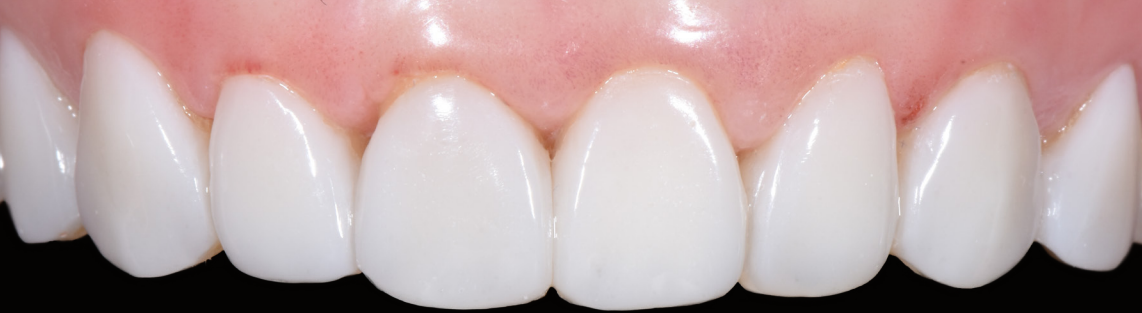Injection Moulding

Case study and technique guide

Dr. Anthony Tay





A smile makeover is an aesthetically-driven dental procedure which aims to rejuvenate a smile and potentially create a life-changing result.

It requires a deep knowledge on smile design, an eye for detail and art form, and the clinical hand precision to create the unique, perfect smile. The treatment planning generally adopts a team approach, involving the patient, clinician, auxiliary staff and the technician. Communication between patient, clinician and technician is paramount to the success of the smile makeover. While more costly porcelain veneers remain the mainstay in this treatment modality, composite veneers have always been an economical alternative. The treatment plan can similarly begin from a wax-up fabricated by the technician, before emulating the design in the patient's mouth, via a freehand approach. The difficulty lies in accurately transferring the exact prototype tooth form and shape into the final delivery, and this skill can take years to master.

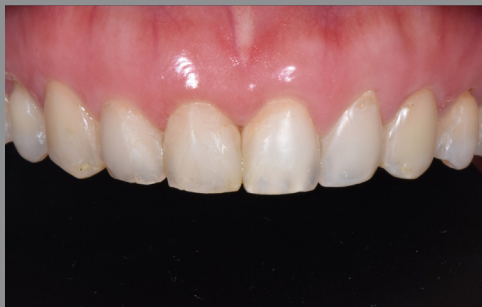With the development of composite filler technology, we are excited to share a predictable smile makeover workflow involving the latest G-ænial™ Universal Injectable composite, perfectly complemented by EXACLEAR™ transparent PVS material. The technique involves replicating the exact smile design template from a wax-up using EXACLEAR™ PVS material, preparing the teeth, and restoring the surfaces with G-ænial™ Universal Injectable composite, utilising the injection moulding technique. Interproximal finishing is carried out before finishing and polishing is completed on the labial veneer surfaces. This methodical approach is simple to follow and shortens the learning curve of smile makeovers with composite veneers. It is especially useful for cases with ideal alignment, such as post-orthodontic shade and surface rejuvenation.

In this clinical case, the female patient presented with failing, thin composite veneers that were carried out after her orthodontic treatment was completed. She was also dissatisfied with the proportion, size and shade of individual teeth. A thorough discussion was held and the patient preferred a more conservative option of composite veneers from teeth 14 to 24, in particular using the injection approach.

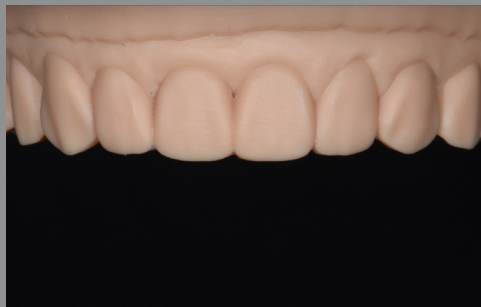Clinical tips

1. The EXACLEAR™ PVS material has the ideal set consistency for direct vent hole creation, using the sharp tip of the G-ænial™ Universal Injectable metal syringe tip. It is important to remove any excess EXACLEAR™ material from the syringe tip to prevent accidental extrusion and embedment into the actual composite surface.
2. Depending on the technique preferred, one or two vent holes can be utilised. If using two vent holes for the anterior, the holes are situated one on the mesial and one on the distal. This technique eliminates air trapping and reduces the amount of excess.
3. When taking the impression, take care not to press too hard on the silicone, so that all incisal edges are covered with a sufficiently thick layer. This is for the stability of the stent and to avoid potential tearing or deformation of the key.
4. For maximum strength, the injectable composite should be bonded entirely on enamel, with no more than 0.5mm of unsupported composite. This will reduce the risk of chipping.
5. The silicone key should always extend far enough to include at least two teeth distally from the teeth to be treated on both sides. This ensures stability of the key when it is positioned in the mouth and ideal reproduction of aesthetic detail for a more predictable outcome.
6. During the injection, a little bit of overflow is needed to ensure that all small voids at the margins and interproximal spaces are filled.
7. The high transparency of EXACLEAR™ allows effective light-curing through the clear stent leading to a higher conversion rate. It eliminates the air inhibition layer for easier and faster polishing.
8. For excess removal, a blade #12, finishing strips and discs are useful.
9. A dental mouthguard is recommended and prescribed for nightly wear to prevent premature composite chipping, especially for patients who grind their teeth.

Clinical Case



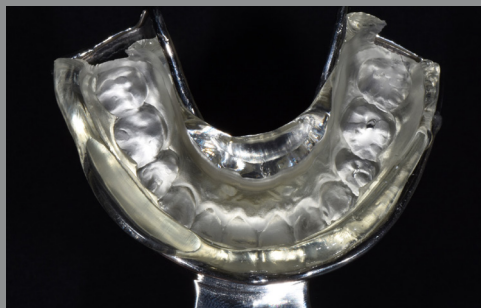1. Young female patient concerned by failing composite veneers with shade and proportion-mismatch. The patient chose to have composite veneers for teeth 14 to 24.



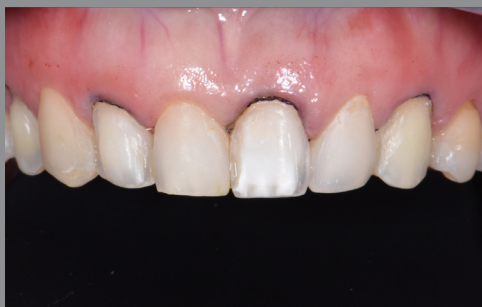2. 3D printed resin model, from a digital wax-up on 3Shape Dental System*, based on her intraoral scan.



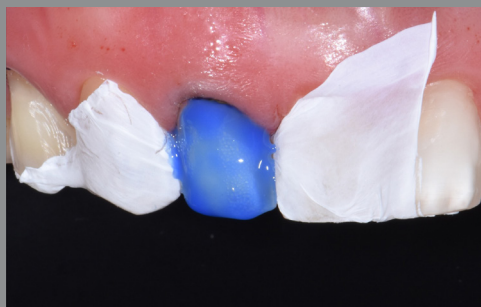3. EXACLEAR™ clear PVS material syringed onto a non-perforated mandibular tray to capture an accurate impression of the printed resin model.



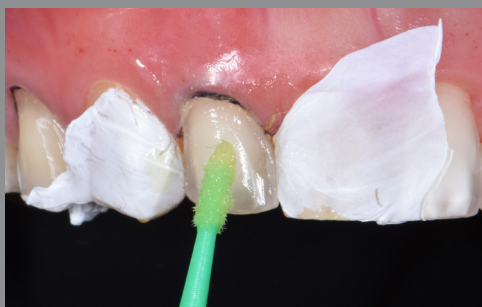4. Highly accurate information of the digital wax-up recorded in the EXACLEAR™ stent.



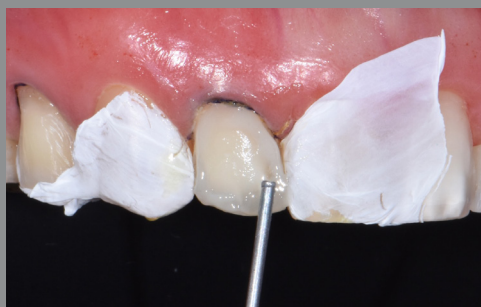5. Alternate tooth preparation technique employed, involving teeth 14, 12, 21 and 23 initially. Retraction cords placement done.



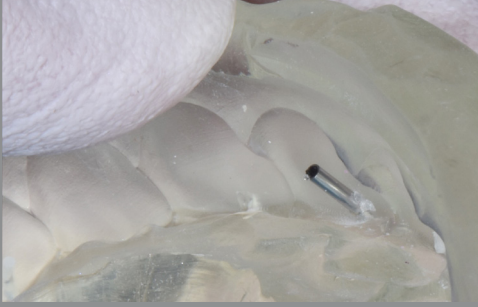
6. Selective enamel etch, one tooth at a time, with isolation using teflon (PTFE) tape to protect the adjacent teeth.



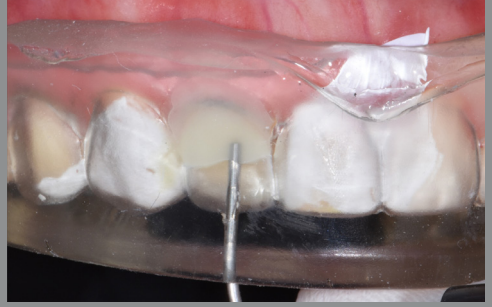7. G-Premio BOND applied to the etched surface.



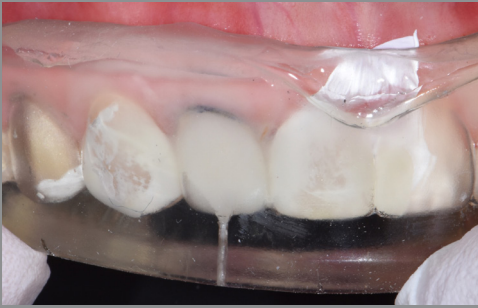8. Margin of the preparation is wetted with an injectable composite, G-aenial™ Universal Injectable shade BW.



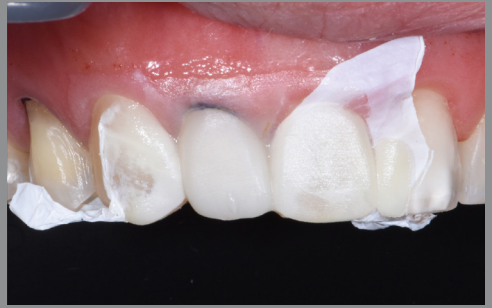9. Create a vent hole in the EXACLEAR™ stent with the tip of the G-ænial™ Universal Injectable composite and carry them together into the mouth.



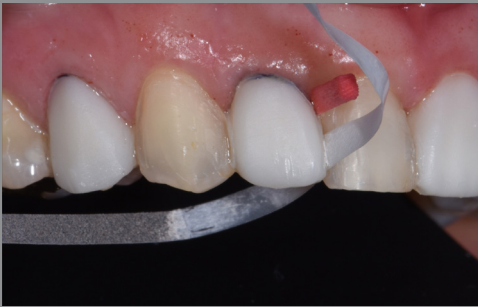10. Injection moulding with G-ænial™ Universal Injectable BW, beginning with a position close to the margin, before withdrawing incisally through the vent hole.



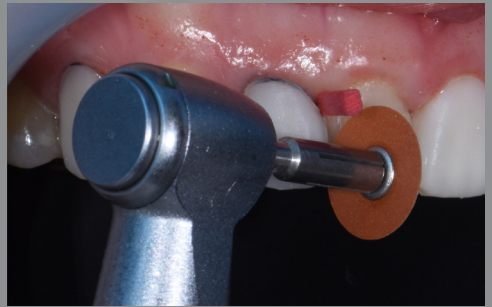11. The high transparency of EXACLEAR™ allows effective light-curing through the clear stent leading to a higher conversion rate. Light-curing is done and injection moulding completed for the first tooth 12.



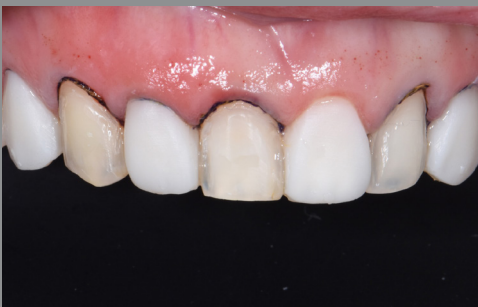12. EXACLEAR™ stent is removed, to allow removal of gross excess.



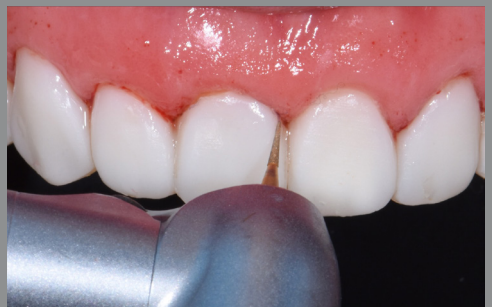13. Interdigital strip refinement.



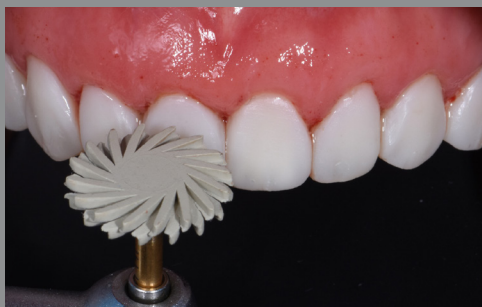14. Polishing disc with wedging to allow better access beyond the line angles.



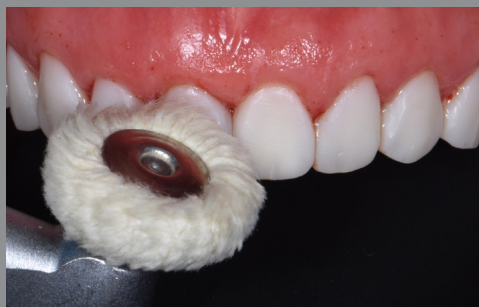15. Gross finishing completed for the first 4 teeth. The same steps are employed for teeth 13, 11, 22, and 24.



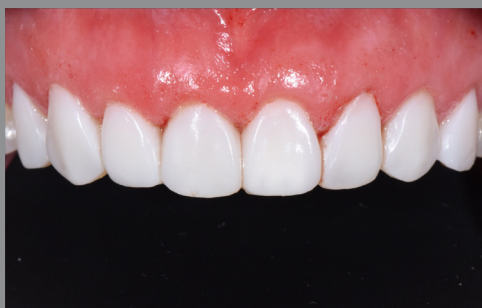16. Gross removal of excess is carried out, followed by finishing and polishing for all the teeth involved. Cervical finishing is achieved with a high-speed needle-shaped fine tip diamond bur.



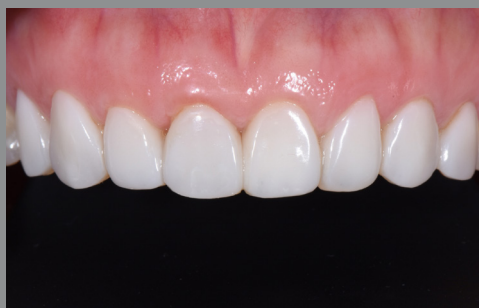17. Polishing with EVE DiaComp Twist[®] pink and grey polisher on a contra-angled slow handpiece.



18. Cotton buff on a contra-angled slow handpiece for high shine and lustre.



19. Immediate post-operative view, awaiting gingiva rebound and recovery.



20. 5-week post-operative review with final shape refinement, finishing and polishing. Patient is extremely satisfied with the result.

Technique:

- Teeth were scanned intra-orally with a digital scanner, and the file was imported into the 3Shape Dental System^{*}, where a digital wax-up was performed to improve the size and shape of the teeth concerned.
- A 3D model was printed based on the digital wax-up.
- EXACLEAR[™] clear PVS was used for the impression of the printed model, using a non-perforated tray for transparency and ease of removal.
- The clear stent was removed and trimmed for intra-oral placement.
- The teeth were prepared using a separate PVS buccal matrix or putty key as a guide. This was utilised to optimise ideal preparation and prevent under or over-reduction of the teeth.
- Retraction cords were placed and a supra-gingival veneer reduction on the buccal surfaces was completed, with a 0.5mm thickness for the composite veneers.
- An individual vent hole was created on the EXACLEAR[™] stent from an inciso-labial angle.
- Adopting a tooth-by-tooth approach, each tooth was isolated with Teflon (PTFE) tape, before selective enamel etch was carried out.
- G-Premio BOND was applied to the surface for effective adhesion.
- An alternate tooth technique was employed to keep the composite within the designated tooth space and prevent excess from bonding interproximally.
- G-ænial[™] Universal Injectable shade BW was first used to wet the margins of the preparations, to minimise air void formation.
- G-ænial[™] Universal Injectable BW was used for the main shade of the veneers to block out any remaining chromatic discrepancy between the teeth.
- The EXACLEAR[™] stent with the G-ænial[™] Universal Injectable syringe and tip were carried together and fitted over the designated teeth.
- Injection moulding was carried out with the light-curing completed through the EXACLEAR[™] stent.
- The EXACLEAR[™] stent was removed to allow gross excess removal and provisional finishing.
- The injection moulding step was then carried out for the other teeth similarly.
- Interdental and buccal finishing and polishing ensued.
- Patient was reviewed after 5 weeks for minor shape correction and final polishing.
- The final result shows beautiful surface lustre that is close to porcelain, and the patient was overjoyed with this predictable smile makeover.

* Not a trademark of GC Corp.



Since 1921
Towards Century of Health

T: +65 6546 7588
F: +65 6546 7577

W: sea.gciasidental.com
E: gcasia@gc.dental